

## Research Article

# Update of Novel Use of Polymethyl Methacrylate (PMMA) Microspheres in the Treatment of Infra-Orbital Rhytids

Mani N<sup>1\*</sup>, Mani M<sup>1</sup>, Sauder D<sup>2</sup>, Sauder MB<sup>3</sup> and Bothwell MR<sup>4</sup>

<sup>1</sup>La Jolla Cosmetic Laser Clinic and California Retinal Associates, San Diego, USA

<sup>2</sup>Department of Dermatology, University Hospital at Princeton, USA

<sup>3</sup>Boston, Massachusetts, USA

<sup>4</sup>Department of Surgery and Otolaryngology, University of California San Diego, USA

\*Corresponding author: Nasrin Mani, La Jolla Cosmetic Laser Clinic, 7720 Fay Ave, La Jolla, CA 92037, USA

Received: October 03, 2016; Accepted: November 22, 2016; Published: November 23, 2016

## Abstract

**Introduction:** Update and expansion of 2013 study investigating the use of Polymethyl Methacrylate (PMMA) microspheres injection for rhytids and infra-orbital rejuvenation.

**Methods:** A retrospective case series of 395 patients for evaluation of long-term complications including lumpiness and granuloma from infraorbital PMMA injection performed in an outpatient cosmetic dermatology clinic by single senior provider (NM).

**Results:** With an additional 3-5 year for follow up from the original study, twenty-four (6.1%) of the 395 patients developed nodularity as a complication. Sixteen of the 395 (4%) presented later than 90 days. The average time to first sign of complication was 1.18 year with a range of 11 days to 3.8 years. Median time was .82 years or 9.8 months. Age, race, or prior blepharoplasty, facelift, or skin-type were not associated with increased complication risk. Twenty patients resolved with multiple steroid injections averaging 3.95 injections to resolution. Two were lost to follow up. Two have had ongoing injections with one of the two undergoing surgical resection of multiple infra-orbital and peri-oral granulomas.

**Conclusion:** Injection of permanent PMMA filler using a subdermal technique in the context of infra-orbital rejuvenation is possible with clinically significant cosmetic benefit. Complication rates are consistent with those previously reported for on and off-label indications. Since this is an off-label use of PMMA in the infra-orbits significant caution must be taken. Should this technique be utilized, it is recommended to do so using serial injections in the epi-periosteal plane with purposeful under correction.

**Keywords:** Infra-orbital; Rhytids; Polymethyl methacrylate (PMMA) microspheres; Rejuvenation; Filler

## Introduction

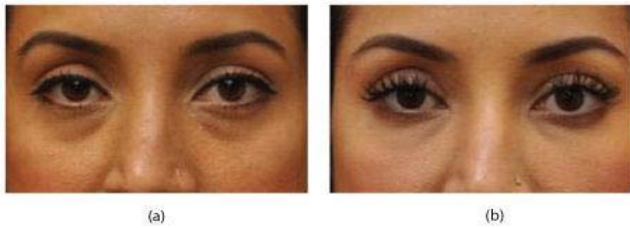Soft tissue fillers are continuing to increase in popularity throughout North America and worldwide as a means of wrinkle and fold reduction. A 3% increase in soft tissue fillers was noted in one year from 2013 to 2014 in the American Society of Plastic Surgery report 2014 [1]. Overall satisfaction using PMMA has been demonstrated as “satisfied or very satisfied” at 82% at 6 months, 78% at 12 months and 84% at 60 months by Cohen in the nasolabial fold [2]. Yet fillers are implants and essentially foreign bodies that can potentially trigger an inflammatory response in some individuals [3].

In 2013, this group’s first retrospective case series involving 289 subjects reported the use of serial PMMA (polymethyl methacrylate) microspheres injections for infra-orbital rejuvenation [4]. The data from the series demonstrated a nodular complication rate of 1.4%. Yet, the study was limited due to the 14-month follow-up period. Cohen et al reported 4- to 5-year complication rates with PMMA injections as 5 out of 69 patients with 6 late adverse complications in 272 rhytids injected (2.2%) developing “lumpiness” at 2-5 years. The rhytids treated were in the glabella, nasolabial folds, radial upper

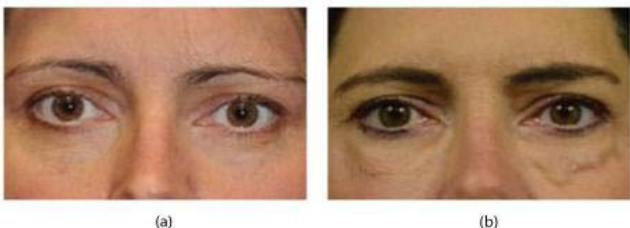lip lines, and corners of the mouth [5]. A follow-up study in 2007 demonstrated that 10 of 145 patients (6.9%) developed “lumpiness” with 8 considered mild, 1 moderate and 1 severe [6]. This study aims to better characterize the complication rate of infraorbital PMMA injections with a follow-up similar to Cohen et al.

## Materials and Methods

395 patients were re-evaluated for long-term efficacy and complications in an outpatient cosmetic dermatology clinic evaluated and treated by one senior provider (NM) for infraorbital rejuvenation with PMMA. The Microsoft Excel 2010 (Redmond, Washington, USA) from the prior study was used and updated to 2016 with numeric identifiers replacing patients identifying features to preserve anonymity. Data were then transferred into SPSS database version 23 (IBM Corporation, Armonk, NY, USA) for statistical analysis. Basic demographics data were analyzed with calculation of the frequency, mean, median, minimum, and maximum of variables. Due to the nonparametric type of data, chi-square analysis was performed to analyze independent variables and their influence on statistical outcomes.



**Figure 1:** (a) Patient 1 preinjection: Patient with moderate infraorbital hollowness. (b) Patient 1 postinjection: Patient post PMMA requiring no further follow up.



**Figure 2:** (a) Patient 2 preinjection: Patient with severe infraorbital hollowness. (b) Patient 2 postinjection: 5 years after PMMA injection with suspected granuloma complication. Right side has acceptable result. Left infraorbital rim with granuloma with possible migration to lower rim position.

## Technique

The majority of patients were injected using the subdermal fanning/ threading technique described by Mani 2013 [4]. The authors would now recommend deep needle droplet injections in the epi-periosteal plane.

## Results

The study is a retrospective case series of 395 patients that underwent 1-7 injections of PMMA filler bilaterally to the infra-orbital region from February 2009 to September 2015. The chart review was completed in May 2016. Three hundred fifty-six patients were female and 39 were male. The average age at first injection was 49 years old with standard deviation of 11.5 years. Patients' race and skin type were diverse: Caucasian (262), Hispanic or South/Central American (54), and Middle Eastern (39), Asian (17), African American (4), other (19). Fitzpatrick skin type of patients varied from type 2 (1) type 3 (235), type 4 (154), type 5 (3) and type 6 (1). Age, race, or Fitzpatrick score were not significant contributors to complication.

As of May 2016, 24 nodular complications in the infra-orbital area or 6.1% were noted in the 395 patients. The average time to first sign of complication was 1.18 year with a range of .03 (11 days) to 3.8 years. Median time was .82 years or 9.8 months. Sixteen of the 24 (4%) had complications presenting later than 90 days as a technique reported by Cohen to confirm an immunological process. Per Cohen, granuloma surveillance events were divided into 2 groups based on time of onset. Early lesions were those symptoms that developed within 90 days of the last injections of implant material. These typically included ectopically placed implant material, either too superficial, misplaced laterally or simply excess implant material that becomes evident only after the procedure-induced swelling has subsided. In addition, many patients naive to injectable dermal fillers may report

the ability to feel or palpate a normal implant. Thus, symptoms or findings appearing during this 90-day time interval were generally considered to be associated with the implantation procedure itself and were not believed to represent an immunologic process and not included as granulomas. Late lesions were those symptoms or findings that arose 90 days or longer after the last implant injections. After this period had elapsed, any changes that occurred were considered to be potentially because of a granulomatous process [2].

Forty-one or 10.4% had had prior blepharoplasty, which was not statically associated with an increase complication risk which was a change from prior report. Of the 24 patients who had complication, only 5 had blepharoplasty. Sixty or 15.2% had had prior facelift. Prior facelift was also not statistically associated with increased risk of nodule formation.

Six of the patients (1.5%) who underwent infra-orbital injection had nodular complication from PMMA filler elsewhere at other injection sites, predominately peri-oral. Other injection sites included: glabella, nasolabial, peri-oral, and temporal. This complication rate at sites other than infraorbital was consistent with Cohen's 2006 findings (2.2% complication rate) [5].

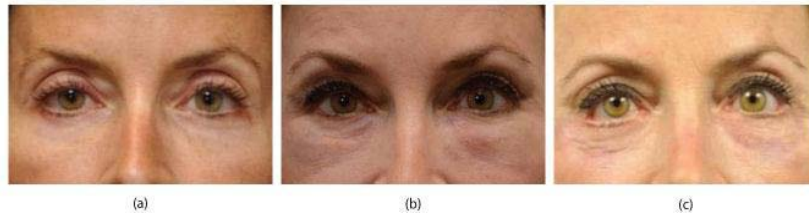
Twenty patients resolved with multiple steroid injections averaging 3.95 injections of 0.1 to 0.5ml of 40mg/kg intra-lesional kenalog. Of the remaining four: two were lost to follow up and two have had ongoing injections with one of the two undergoing surgical resection of multiple infra-orbital and peri-oral granulomas (Figure 1 and 2).

The patient requiring surgical excision of infra-orbital nodule was a 49 year-old Caucasian woman with history of prior blepharoplasty, Lasik surgery and prior infraorbital hyaluronic acid (HA) filler. She received the HA filler 2 years prior to the PMMA injection and required 4 hyaluronidase (Vitrace, Bausch+Lomb, Rochester, NY) injections due to complications. The patient received her first PMMA filler at author's clinic in July of 2011. At 1.49 years after the initial PMMA injection a nodule was noted and the patient received 0.1-0.5 ml of intra-lesional triamcinolone at 40mg/ml. No improvement was noted at 6 weeks and a 50:50 mixture of triamcinolone and 5% fluorouracil (5-FU) was utilized as per Vent and Lemperle [7,8]. The nodular complication did not respond significantly to either injection. As such, the patient underwent subtotal resection of PMMA confirmed granuloma from infraorbital region with a transconjunctival approach per patient request with moderate results. Bacterial cultures were negative for growth (Figure 3).

## Discussion

Granulomatous reactions have been reported following injection of both permanent and temporary fillers. While the author's 2013 paper demonstrated a relatively low complication rate, 1.4%, with longer follow-up a significantly higher nodular complication rate, 6.1% of patients, is now noted. Yet, this is consistent with prior studies of PMMA injections elsewhere resulting in lumpiness, 6.8% of patients [5]. Although the data seems to be reproducible independent of anatomical location, a complication of 6% equates to more than 1 in 20 patients experiencing this complication.

PMMA or foreign body granuloma was noted in biopsy



**Figure 3:** (a) Patient 3 pre injection: 50-year-old woman with moderate infraorbital hollowness desiring treatment. (b) Patient 3 post injection: 55-year-old woman with nodular adverse reaction to PMMA just before surgery for removal of granuloma. (c) Patient 3 post surgery: 56-year-old post excision of PMMA nodules. Note right eye lower cicatricial ectropion will require further treatment.

specimen of patient (Figure 3). Cultures taken were negative. While a majority of patients seem to tolerate PMMA without nodule or granuloma formation, why some patients have cosmetically serious nodules remains elusive. The trigger leading to the generation of foreign body granulomas is a matter of debate between a delayed-type hypersensitivity reaction versus a low grade infection in which bacteria have formed an activated biofilm organized in the filler depot even though culture is either not taken or negative [9].

Previous reports have noted the development of granulomas may be delayed as much as 6 to 24 months after treatment with PMMA [7,10]. This study of 395 patients shows adverse reactions initially occurring as late as 3.8 years or 36 months post injection. Thus, continued follow-up of these 395 patients will be done and is suggested to any practitioner using PMMA. The majority of the nodular complications resolved with intra-lesional triamcinolone and this should be considered first line therapy for revision.

The infraorbital pocket is a delicate area that should be approached with caution. Gladstone and Cohen discussed the wide variation of skin thickness and texture within the facial cosmetic units especially in the “I” zone. While a tell-tale sign of aging is in the peri-orbital region where there is a loss of volume and subsequent hollowing of the eyes, the eyelids and periorbital have a very thin dermis and injections into this layer will inevitably lead to lumpiness and potential granuloma whether the practitioner is injecting hyaluronic acid, calcium hydroxylapatite, or poly-L-lactic acid [11]. In 2014, Lemperle cautioned specifically about nodule formation when injecting into the orbicularis muscle. In the case of dark shadowed eyelids, the orbital rim has to be augmented strictly epi-periosteally by scratching the needle tip on the bony orbital rim. Care has to be taken to avoid injecting into the orbicularis muscle because of subsequent nodule formation [7].

Patient appears to show inferior filler migration (Figure 2). Jordan and Stoica reported 3 patients with infraorbital filler migration and proposed possible mechanisms. Motion of the orbicularis muscle or muscles of facial expression could promote dislocation of a filler [12]. Additionally, when injecting in the subdermal fanning technique as described above it can be difficult to differentiate between the subdermal area and the orbicularis muscle. While the layers are well described educationally, clinically it can be difficult to differentiate between layers especially with a fine gauged needle. Consequently, the subdermal injection may travel into the orbicularis muscle.

The initial study cautioned against the subdermal injection of PMMA status-post blepharoplasty planes. It was hypothesized that

blepharoplasty may disturb the dermal-subdermal and thus interfere with smooth injection of the PMMA agent as scar tissue and does not allow the even distribution of the material. If a PMMA filler was still considered appropriate in patients with a history of blepharoplasty, it is recommended to use the deep needle droplet injections in the epi-periosteal plane [4]. However, contrary to the original study, longitudinal follow-up does not demonstrate a statically significant increase in nodule formation with a history of blepharoplasty. Of the 24 patients who had nodule complication, only 5 had blepharoplasty.

Prior reaction to any filler should be considered a relative contraindication to infraorbital PMMA injections. Even if there was a prior reaction with the perceived improvement with hyaluronidase, due to the longevity of PMMA without an antidote, other modalities of infraorbital rejuvenation should be promoted over any fillers in these patients.

The most significant limitation to the study was the lack of biopsy analysis. The one surgical patient had PMMA confirmed granuloma but also then had cicatricial ectropion resultant from the biopsy. The risk of biopsy confirmation was weighed versus continued conservative management. With continued improvement in nodularity, it was deemed best practice to avoid biopsy in this area if possible.

Limitations to the study also included the patients not considering medical issues in a ‘spa’ environment and not reporting possible comorbidities such as previous surgery, previous injectable fillers, and possible autoimmunity. Two patients were also lost to follow up.

## Conclusion

In conclusion, this study has shown that injection of a permanent PMMA filler using a subdermal technique in the context of infra-orbital rejuvenation is possible with clinically significant cosmetic results. However, this is an off-label use of a permanent filler not approved for use in the infra-orbits, and significant caution must be taken with full disclosure to the patient. Further follow-up of this cohort of patients demonstrated additional complications at a higher rate than initially reported yet consistent with other studies. Longer term follow-up seems to be necessary and beneficial to identify and manage any complications as early as possible.

## References

1. American Society of Plastic Surgeons. 2014.
2. Cohen S, Dover J, Monheit G, Narins R, Sadick N, Werschler W, et al. Five-year safety and satisfaction study of PMMA-Collagen in the correction of nasolabial folds. *Dermatol Surg*. 2015; 41: 302-313.

3. Eun S, Hyun C, Deuk L, Sung K. Periorbital lipogranuloma related to filler migration: a rare complication of facial fillers. *J Cos Las Ther*. 2014; 16: 149-150.
4. Mani N, McLeod J, Sauder M, Sauder D, Bothwell M. Novel use of polymethyl methacrylate (PMMA) microspheres in the treatment of infraorbital rhytids. *J Cosmet Dermatol*. 2013; 12: 275-280.
5. Cohen SR, Berner C, Busso M. ArteFill: A long-lasting injectable wrinkle filler material: Report of a controlled, randomized multicenter clinical trial of 25 subjects. *Plastic Reconst Surg*. 2006; 118: 64S-76S.
6. Cohen S, Berner C, Busso M, Clopton P, Hamilton D, Romano J, et al. Five-Year Safety and Efficacy of a Novel Polymethylmethacrylate Aesthetic Soft Tissue Filler for the Correction of Nasolabial Folds. *Dermatologic Surg*. 2007; 33: S222-S230.
7. Vent J, Lemperle G. Prevention and Treatment of Complications after Polymethylmethacrylate-Microspheres Injections. *Facial Plast Surg*. 2014; 30: 628-634.
8. Lemperle G, Rullan P, Gauthier-Hazan N. Avoiding and treating dermal filler complications. *Plast Reconstr Surg*. 2006; 118: 92S-107S.
9. Kadouch J, Kadouch D, Fortuin S, Rozelaar L, Karim R, Hoekzema R. Delayed-Onset Complications of Facial Soft Tissue Augmentation with Permanent Fillers in 85 Patients. *Dermatol Surg*. 2013; 39: 1474-1485.
10. Lemperle G, Romano J, Busso M. Soft tissue augmentation with artecoll: 10 year history, indications, techniques and complications. *Dermatol Surg*. 2003; 29: 573-587.
11. Gladstone H, Cohen J. Adverse effects when injecting facial fillers. *Sem Cutan Med Surg*. 2007; 26: 34-39.
12. Jordan D, Stoica B. Filler Migration: A Number of Mechanisms to Consider. *Ophthal Plast Reconstr Surg*. 2015; 31: 257-262.